

Photographic Essay

Choroidal neovascularization after accidental macular damage by laser

Márcio B Nehemy MD PhD, Leonardo Torqueti-Costa MD, Érika P Magalhães MD, Daniel Vítor Vasconcelos-Santos MD and Ado Jório Vasconcelos MD

São Geraldo Eye Hospital, Federal University of Minas Gerais and The Vision Institute, Belo Horizonte, Minas Gerais, Brazil

ABSTRACT

A 30-year-old male physics professor was examined 2 months after being accidentally hit by a laser beam in his left eye. He complained of abrupt vision loss and central scotoma after the laser accident, with stabilization of the vision thereafter. At presentation, he presented best-corrected visual acuity of 6/18 in the left eye. Fundoscopy disclosed a slightly elevated foveal brownish lesion, surrounded by a subtle subretinal haemorrhage. Fluorescein angiography demonstrated a hyperfluorescent foveal lesion with staining and a slight leakage in the late phase, characterizing a fibrovascular choroidal neovascularization (CNV). Optical coherence tomography showed a discrete increase in retinal thickness and a subretinal fibrotic CNV. Visual acuity remained stable during the follow up (4 months). CNV after laser injury is rare. The evolution of this case suggests that CNV, after an accidental laser injury, in a healthy macula of a young patient might have a self-limited course and a relatively good prognosis.

Key words: choroidal neovascularization, laser instruments, subfoveal choroidal neovascularization.

INTRODUCTION

Laser eye damage has been reported since 1964 when lasers were just beginning with different applications use.^{1,2} There have been several published reports of laser injury, but there is only one report of choroidal neovascularization (CNV) following laser trauma, which was after using an Nd:YAG laser. We report a case of an accidental macular injury by a Ti:Sapphire laser that caused a secondary CNV.

CASE REPORT

A 30-year-old male physics professor was examined 2 months after being hit by a laser beam in his left eye. He

complained of a sudden vision loss and central scotoma after the laser accident, with stabilization of the vision thereafter. The patient was performing a laboratory physics experiment when the trauma occurred.

The accident happened with a Ti:Sapphire laser (Spectra-Physics model 3900S), pumped by an Argon laser (Coherent Innova 70). The Spectra-Physics 3900S is a tuneable laser that enhances a given wavelength from the luminescence profile of the Ti:Sapphire crystal. The pumping laser has 5 W power output and the luminescence profile for the tuneable laser is 720–860 nm in wavelength. At the time of the accident, the laser was set at the maximum power output, with wavelength around 780 nm and power output around 1 W. The laser beam was approximately 2 mm in diameter and was reflected by one mirror before reaching the eye.

At presentation, 2 months after the injury, ocular examination revealed best-corrected visual acuities of 6/6 in the right eye and 6/18 in the left eye. Anterior segments and applanation tonometry were normal in both eyes. Fundoscopy disclosed a normal right fundus, but in the left eye a minimally elevated foveal brownish lesion, measuring about 275 μm , surrounded by a subtle subretinal haemorrhage was noted (Fig. 1).

Fluorescein angiography demonstrated a hyperfluorescent foveal lesion with staining and a slight leakage in the late phase, consistent with an involuting CNV (Fig. 2). Early phase indocyanine green angiography revealed a foveal hypofluorescent spot (Fig. 3). Optical coherence tomography showed a discrete increase in retinal thickness and a subretinal CNV with mild macular oedema (Fig. 4).

The patient was re-examined 1, 2 and 4 months later. Visual acuity remained stable at review.

DISCUSSION

Almost all reported cases of laser eye injury have involved short Q switched laser pulses, and have produced intraocular haemorrhages, indicating that they were caused by

■ Correspondence: Dr Márcio Nehemy, Instituto da Visão, Rua dos Otoni 881/13 Andar, Santa Efigênia, Belo Horizonte, Minas Gerais, Brazil.

Email: ivisao@ivisao.com

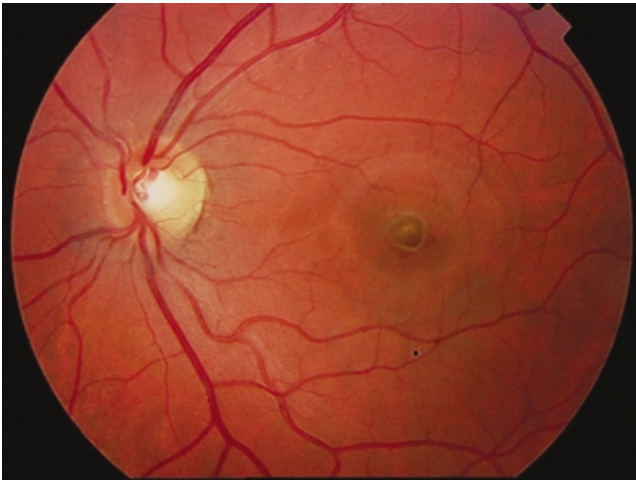


Figure 1. Colour fundus photography of the left eye showing a foveal brownish lesion, surrounded by a thin pale halo and a subtle subretinal haemorrhage.

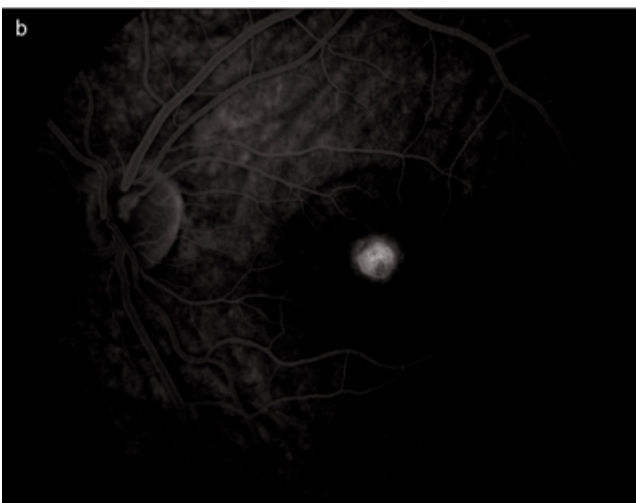
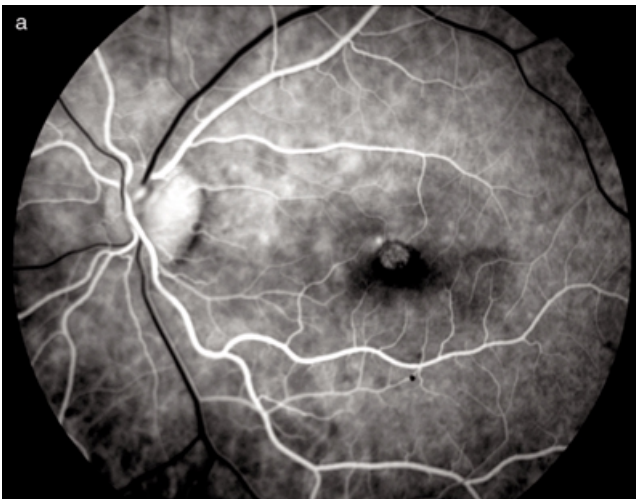

Figure 2. Fluorescein angiography (a) early and (b) late, revealing choroidal neovascularization with hyperfluorescence by staining with minimal leakage.

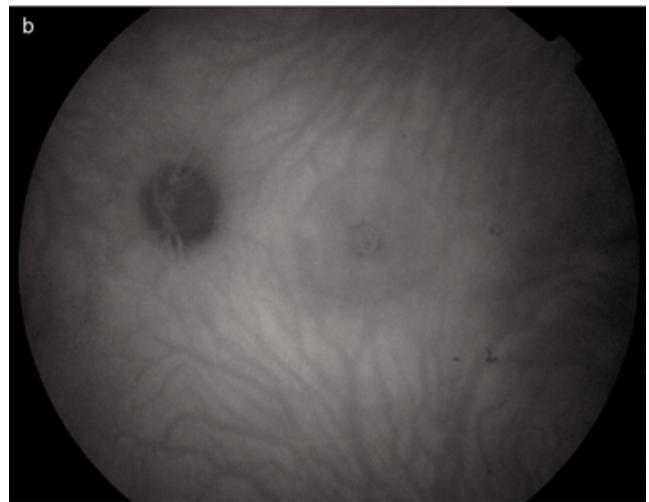
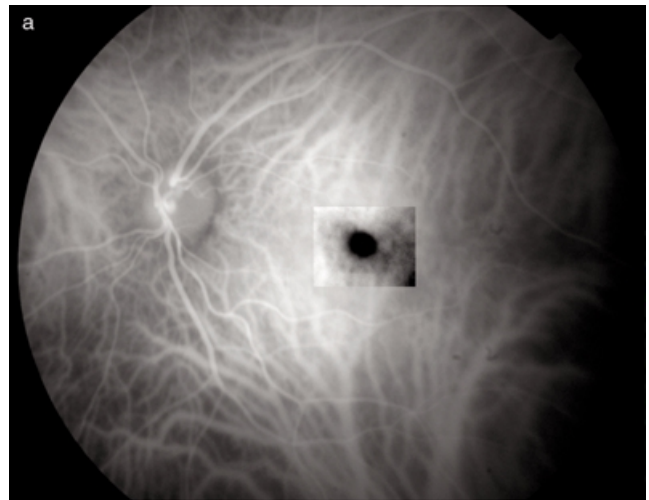


Figure 3. Indocyanine green angiogram. (a) Early phase, showing a hypofluorescent spot. (b) At a late phase, there was a slightly hyperfluorescent spot surrounded by a hypofluorescent halo. There was also another hypofluorescent ring measuring around 3000 μm that correspond to a remnant of the subretinal haemorrhage.

high energy levels.³ Virtually all reported eye laser injuries can be avoided if proper safety measures are taken, especially if wearing protective goggles is made compulsory.

The development of chorioretinal scarring is the most frequently reported severe complication. Other complications include preretinal membrane, macular pucker, and macular hole.^{3,4} In 1999, Roider *et al.* described the first case of CNV after an accidental laser injury by a military range finder, an Nd:YAG laser operating at 1064 nm. To our knowledge, the present case is the first of CNV secondary to an accidental injury caused by the Ti:Sapphire laser (wavelength around 780 nm and power output around 1 W, at the time of the incident). Experimental findings suggest that the instantaneous overheating of tissue leads to secondary mechanical expansion of choroidal tissue with subsequent rupture of choroidal vessels and Bruch's membrane,

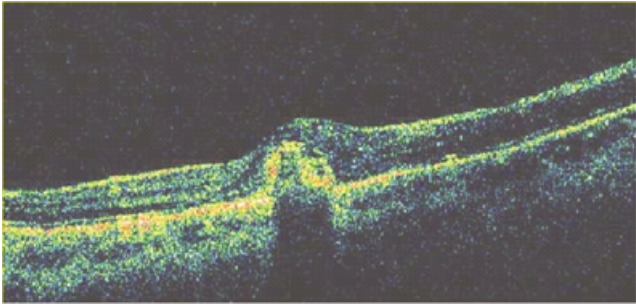


Figure 4. Optical coherence tomography showing subtle intraretinal microcysts with thickening and irregularity of retinal pigment epithelium – Bruch's membrane – choriocapillaris complex, compatible with inactive choroidal neovascularization.

with consequent development of CNV.⁵ Moreover, some studies suggest that the macular region is predisposed to creation of laser-induced CNV in monkeys.⁶

As the fluorescein angiography and clinical findings in our patient were stable, intervention was not recommended. However, the patient is at risk of further CNV due to the

pre-existing scar and is therefore being kept under observation. The evolution of the CNV in this patient aged 30 years demonstrated a benign course, but it emphasizes the point that working with lasers can be dangerous and appropriate eye wear should be mandatory.

REFERENCES

1. Curtin TL, Boyden DG. Reflected laser beam causing accidental burn of retina. *Am J Ophthalmol* 1968; **65**: 188–9.
2. Zweng HC. Accidental Q-switched laser lesion of human macula. *Arch Ophthalmol* 1967; **78**: 596–9.
3. Barkana Y, Belkin M. Laser eye injuries. *Surv Ophthalmol* 2000; **44**: 459–78.
4. Alhalel A, Glovinsky Y, Treister G et al. Long-term follow up of accidental parafoveal laser burns. *Retina* 1993; **13**: 152–4.
5. Roeder J, Buesgen P, Hoerauf H, Schmidt-Erfurth U, Laqua H, Birngruber R. Macular injury by a military range finder. *Retina* 1999; **19**: 531–5.
6. Shen WY, Lee SY, Yeo I et al. Predilection of the macular region to high incidence of choroidal neovascularization after intense laser photocoagulation in the monkey. *Arch Ophthalmol* 2004; **122**: 353–60.